

The native turkey (*Meleagris gallopavo*): male morphophysiology

López-Pérez, Elvia¹; Gallegos-Sánchez, Jaime²; Pró Martínez Arturo²;
Cuca-García, Juan M.²; Calderón-Sánchez, Francisco³; Herrera-Barragán, José Antonio^{4*}

¹ Universidad Autónoma Chapingo. Departamento de Zootecnia. Carretera México-Texcoco km 38.5, Chapingo, Texcoco, Estado de México. C.P. 56230.

² Colegio de Postgraduados Campus Montecillo. Carretera México-Texcoco km 36.5, Montecillo, Texcoco, Estado de México. C.P. 56230.

³ Colegio de Postgraduados Campus Puebla. Carretera Federal México-Puebla km 125.5, Santiago Momoxpan, Puebla, México. C. P. 72760.

⁴ Universidad Autónoma Metropolitana Xochimilco. Calzada del Hueso 1100, Villa Quietud, Coyoacán, Ciudad de México. C. P. 04960.

* Corresponding author: herreraaves@gmail.com; jherreraab@correo.xoc.uam.mx

ABSTRACT

Objective: To describe the morphophysiology and reproductive characteristics of the male turkey.

Methodology: An analysis based on the practical experiences from over 10 years with the native Mexican turkey was developed and complemented with literature reports.

Results: In Mexico the production management is customs based on traditions and beliefs. In their reproductive morphophysiology, the epididymis absence stands out, as well as a rapid testicular growth during the breeding season, which is controlled by the photoperiod.

Limitations of the study: Native turkey farming is practiced in backyard, in marginalized and low-resource areas that have no strategies (nutritional and reproductive) to improve their production.

Conclusions: The anatomical, morphological, physiological and reproductive characteristics of the native Mexican turkey were documented. The knowledge on these characteristics will allow to develop feeding and reproductive strategies to improve the productive and reproductive performance of the native turkey and preserve their genetic resources.

Key words: native species, bird, conservation, spermatozoa, Mexican species.

Citation: López-Pérez, E., Gallegos-Sánchez, J., Pró-Martínez, A., Cuca-García, J. M., Calderón-Sánchez, F., & Herrera-Barragán, J. A. (2021). The native turkey (*Meleagris gallopavo*): male morphophysiology. *Agro Productividad*. <https://doi.org/10.32854/agrop.v14i8.2105>

Editor in Chief: Dr. Jorge Cadena Iñiguez

Received: February, 2021.

Accepted: August, 2021.

Estimated publication date:

September, 2021

This work is licensed under a Creative Commons Attribution-Non-Commercial 4.0 International license.



INTRODUCTION

Since ancient times, native “guajolotes” (*Meleagris gallopavo* Linn) were part of the Mexican diet. This bird, one of the most important during the conquest of America, was introduced from Mexico to Spain and from there to other countries, including England, where it is believed that its productive capacity was improved. Later, it returned to America, specifically to North America, where it hybridized with wild species and gave rise to enhanced turkeys (Crawford, 1992). The productive practices for native turkeys are based on customs, traditions and beliefs dating back to the conquest; its breeding is still



practiced nationwide, mainly among families in rural and peri-urban areas for which represents an economic income, as well as an alternative to improve their animal protein consumption, since its meat contains 20 to 23% protein (López *et al.*, 2011). The presence of native turkeys is important for backyard producers, most likely for their toughness, the preference for their meat in religious and social festivities of rural families, and because it continues to breed in precarious conditions. Currently, consumers are more insistently requesting that both plant and animal products should be produced without insecticides, pesticides or food additives. This scenario could be a stimulus for small producers who are able to produce with these requirements without major problems; however, implementing nutritional and reproductive strategies to improve production would be appropriate, so that at some point, turkey farming at rural scale becomes a family business. However, little is known about the reproductive physiology of the native Mexican turkey, therefore this work focuses on sharing practical knowledge related to the reproductive management that may help in this specie's conservation.

DESCRIPTION

There is sexual dimorphism, the size of the males varies according to its nutritional status and region of origin. Ramírez and Ramírez (2012) reported a total average length of 861 mm. As for their body weight, in communities of Puebla and Tlaxcala states, one-year-old animals have been found ranging in weight from 5 to 8 kg. At the experimental farm of the Animal Husbandry Department of the Universidad Autónoma Chapingo, with a diet based on sorghum and soybean paste, specimens have weighed an average of 8 kg at 9 months of age, and some animals have even weighed up to 11 kg by year one.

The male has a robust body and funny appearance due to the loose skin of its head and neck (dewlap), caruncles or corals and an erectile fleshy appendage or mucus. The color of the head varies from bluish white to purple, on the chest they have a hairy appendage called beard, which is important in some rural communities because animals are selected for consumption or production if they have this appendage and thick vibrissae come out of it (Figure 1).

Males usually have the habit of opening the feathers of the caudal region in a fan form. The plumage coloration varies, although the most common are black or ocellated and variants of them, with iridescent and green tones or without them, white or albino, brown and grey are less frequent to find, but much less the so-called cinnamon (Figure 2).

MORPHOLOGY AND REPRODUCTIVE PHYSIOLOGY

The structures that integrate the reproductive apparatus of the male turkeys (Figure 3) are: testes, vas deferens and erectile papilla, which ends in the cloaca.

Testicles. They locate at the abdominal cavity, on both sides of the vertebral column posterior to the lungs and anterior to the kidneys. They are kidney-shaped, cream colored in young turkeys and lighter in mature and old males. In dissections performed in 18 months and 9 years old animals by the authors, it was found that there is a testicular regression (reduction of weight and size) in old animals.

Sperm production is photoperiod dependent, increasing as daylight hours increase and decreasing as day length decreases. Each gonad is attached by ligaments adjacent to the adrenal glands (Herrera *et al.*, 2014) and contain seminiferous tubules that drain into the vas deferens. Each of the vas deferens ends in the erectile papilla or (phallus). It is worth




Figure 1. Distinguishing characteristics of the native turkeys (*Meleagris gallopavo* Linn). 1) appendix (mucus), 2) dewlap, 3) caruncles, and 4) wattle.



Figure 2. Plumage color variations in turkeys (*Meleagris gallopavo*).

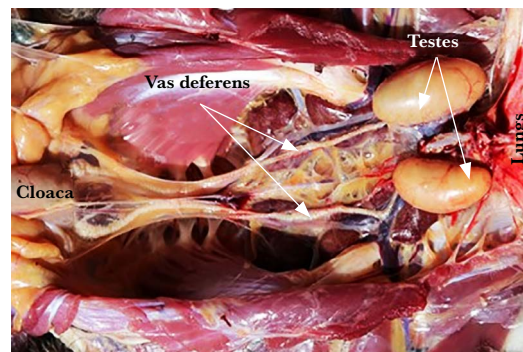


Figure 3. Structures of the reproductive system of male turkeys (*Meleagris gallopavo*).

mentioning that the presence of the epididymis is questionable, since macroscopically and histologically there is no evidence, as well as the presence of spermatozoa with different physiological status (Gonzalez *et al.*, 2019).

In the network of seminiferous tubules are the Sertoli cells, whose functions are to contribute to the maintenance of the seminiferous tubule structure, act as nurse cells for the germ cells that will give rise to spermatozoa, secrete steroids to help in the differentiation of germ cells and phagocytose the remains of the germ cells that degenerated inside the seminiferous tubes. In the spaces between seminiferous tubes are the Leydig cells, which produce steroid hormones in the testis such as testosterone. A series of changes occur in the seminiferous epithelium, in which the germ cells are transformed into secondary spermatocytes and spermatids, which through a series of morphological transformations called spermiogenesis give place to spermatozoa of elongated shape and with a flagellum. Once spermiogenesis is completed, the Sertoli cells shed the formed spermatozoa into the lumen of the seminiferous tubes, which are then transported to the vas deferens (Abad *et al.*, 2003).

The ejaculate characteristics are described in Table 1, which highlights that the volume of the ejaculate is “low” compared to the volume of improved turkeys (Gee *et al.*, 2004), as well as the sperm concentration, which may relate to the low need for copulation and the high capacity of the turkey hen to maintain viable spermatozoa preserved in the utero-vaginal junction. Once semen is deposited into the female cloaca during copulation (since the phallus of turkeys is rudimentary and there is no true penetration), it enters the urodeal tubular glands and then is gradually transferred to the vagina and from there transported to the utero-vaginal junction-sperm storage tubules (Bakst and Akufo, 2008), from where the sperm will be progressively released and advance to the infundibular zone, where they will fertilize the egg that has been released from the follicle. Turkey sperm can remain viable for up to 60 days in this part of the oviduct (Abad *et al.*, 2003).

Vas deferens. Present caudal to the testicles, elongated in shape with numerous flexuosities where the sperm matures, acquires motility and is transported to the erectile papilla, where seminal plasma is produced (Ricaurte, 2006), since birds lack adnexal glands (prostate and bulbourethral glands). In the last part of the vas deferens there is a dilatation that works as a sperm reservoir.

Table 1. Seminal parameters of ejaculate (n=15) and vas deferens* (n=1).

Parameters	Abdominal massage Vas deferens	Abdominal massage Vas deferens
Ejaculate volume (mL)	0.05	0.04
Sperm concentration ($\times 10^9 \text{ mL}^{-1}$)	3.5	3.5
Sperm motility (%)	84	85
Live (%)	70	70
Dead (%)	30	30
Total length (μm)	87.75 \pm 4.91	87.75 \pm 4.91

Erectile papilla. These are the cloacal lymphatic folds and paracloacal vascular bodies. The latter are filled with lymph at the moment of erection. Lymph is a clear fluid that transudates into the cloaca through the lymphatic folds and can join with semen. When there is an erection, the rounded folds of the cloaca swell, forming a slight protrusion towards the outside of the cloaca and constitute a small canal also known as a phallus (vestigial) through which sperm is evacuated. This phallus increases in volume during copulation, at which time the two cloacae come into contact (Abad *et al.*, 2003) and the semen is passed between them.

Sperm morphology. The turkey spermatozoon is elongated and narrow in shape. It has a total length of 75 to 80 μm , is haploid, devoid of cytoplasm, has an elongated nucleus, with condensed chromosomes and has an acrosome that measures 1.0 to 2.0 μm long. This acrosome allows the sperm to interact with and penetrate the oocyte and fertilize it (Barbas and Mascarenhas, 2009).

Natural reproductive control

The hypothalamic-pituitary system in birds is the main axis that controls the reproductive system. There are two different regions in the adenohipophysis: the anterior region, responsible to produce prolactin, thyroid stimulating hormone (TSH), and adrenocortical stimulating hormone (ACTH), and the posterior region, responsible to produce growth hormone (GH). Some hormones are produced in both regions, such as luteinizing hormone (LH) and follicle stimulating hormone (FSH). Between the nuclei of the hypothalamus there are neural connections, which are involved in the release of hormones such as gonadotropin-releasing hormone (GnRH), gonadotropin inhibitory hormone (GnIH), FSH and LH (Tsutsui *et al.*, 2006); all of which are important in reproduction. However, GnRH is responsible for the release of the adenohipophysis hormones FSH and LH (Bentley *et al.*, 2006). In the case of some wild mammals and birds, reproduction is regulated by the photoperiod and through photoreceptors located in the retina and pineal gland, birds detect seasonal changes (darkness) which are then translated into hormonal signals mediated by melatonin (N-acetyl-5-methoxytryptamine), a substance synthesized in the pineal gland. According to Illnait-Ferrer (2012) sunlight controls melatonin secretion, via the retina and the nervous system. Melatonin production and secretion is stimulated by postganglionic retinal nerve fibers, which pass through the retinohypothalamic tract to the suprachiasmatic nucleus, traverse the superior cervical ganglion and finally, reach the pineal gland. The suprachiasmatic nucleus communicates via neural signals with the pineal gland, being stimulated by the retina which causes the release of melatonin. This neural system is stimulated by darkness and inactivated by light (Hardeland and Fuhrberg, 1996; Tsutsui *et al.*, 2006). Thus, melatonin levels increase during winter and decrease in summer, *i.e.* it is of shorter duration and greater amplitude during long photoperiods, and with prolonged duration and smaller amplitude in short photoperiods (Brandstätter, 2003). Melatonin in birds influences the secretion of GnIH hormone, which prevents the release of GnRH and consequently FSH and LH, with the interruption of reproduction during short photoperiod seasons or the onset of reproduction on long days of 12 hours of light in average (Bentley *et al.*, 2006). If GnRH is not inhibited by melatonin, GnIH will

allow the release of FSH and LH from the anterior pituitary and steroidogenesis leading to spermatogenesis and thus reproductive activity of seasonal species will be initiated (Brandstätter, 2003).

Leydig cells produce testosterone when they are stimulated by LH produced in the pituitary gland, which is responsible for the reproductive processes in the rooster and is believed to be very similar in turkeys. Thus, testosterone maintains libido and courtship activities in the male, is also responsible for the aggressive behavior, it participates in the development and maintenance of secondary reproductive organs and secondary sexual characteristics, and it also has effects on spermatogenesis as it influences mitosis and meiosis. Luteinizing hormone production is stimulated by the secretion of GnRH, which is produced in the hypothalamus due to an external stimulus (*e.g.*, seeing a female), which activates a neuroendocrine mechanism and activates the GnRH-LH-testosterone axis. The increase of testosterone in the blood causes the binding with receptors in the brain from where it increases the excitability of the neural circuits that will make the male try to mate with a female. Another no less important stimulus is light, short or decreasing photoperiods (8 h light) in the prepubertal phase (stimulating FSH production and Sertoli cell multiplication), followed by long or increasing photoperiods (16 h light) in the pubertal phase (stimulating the production of LH, testosterone and spermatogenesis) result in good and long-lasting seminal production (Abad *et al.*, 2003). Seminal characteristics may vary influenced by bird species and strain, physiological status, nutritional status, housing, age and method of semen collection.

MATING

Mating ritual. Courtship in this species is peculiar, the males inflate their bodies, extend or spread their tails in the form of a fan and stand very erect strutting and shaking their feathers as if to show the females their beauty (Figure 4A). They also make characteristic sounds during courtship as if they were gulping something. In other cases, the male makes movements as if he were dancing in the same place (Figure 4B), lowers his wings and tail and sometimes with the latter makes rapid downward movements. Once the male is accepted or attracted by the female (Figure 4C), the female places herself on the ground so that with a trampling ritual the male settles down, lowers his tail and wings, the female puts aside her tail, lowers her wings and copulation takes place with the union of the two cloacae (Figure 4D). When a turkey hen does not have a male to service her and requires it, she places herself on the ground, holds her head erect, raises her tail and lowers her wings; this behavior is performed when the caretaker or another person passes near her.

ASSISTED REPRODUCTION

Artificial insemination. As in other species, artificial insemination (AI) in turkeys consists of placing the sperm content in the female's reproductive tract, in this case the hen's vagina, through other methods than natural mating. In commercial turkey farms, AI is most often used because the male is too heavy to step on the turkey hens. Although native turkeys are not as heavy for this same purpose, the use of this technique can be adequate



Figure 4. Mating of the turkey. A) Strutting and display of plumage with circular walk around the female. B) Repeated dance in front of the female. C) Static acceptance of the female. D) Copulation.

to conserve genetic material of animals with outstanding characteristics or simply to have material available when required, since backyard farming is decreasing and there is a fear that it will disappear. Therefore, it would be convenient for the future to have a bank of genetic material of native turkeys and implement the AI technique in native turkeys.

There are four possible AI protocols: 1) insemination with fresh, undiluted semen; 2) insemination with diluted semen (volumetric dilution) without knowing its quality; 3) insemination with dilution based on an approximate knowledge of the amount of viable sperm per dose; and 4) insemination with cryopreserved semen after having been thawed and diluted with cryoprotectants. The potential of cryopreserving semen is enormous, since native turkey specimens with great genetic potential could be conserved. There is limited research on turkeys and even less on native turkeys, which is why it is necessary to work on this subject. Currently, fresh semen is used in commercial farms, so the procedure to be followed is explained below: Once the semen has been obtained, a sperm evaluation (concentration, viability and motility) is performed by eye, quickly or in detail through the different techniques that exist such as volume of sedimented sperm cells, spectrophotometry, fluorometry, nigrosin/eosine dye; in order to have an idea of the fertilizing capacity of the semen that is to be used, determine the number of doses to supply to the turkey hens and also determine which males produce poor quality sperm in order to proceed with their elimination. The semen is then diluted (minimum 1:1) or used undiluted in the insemination of the turkey hens, the use of which will depend on the time elapsed before its

use. The dilution is done with the objective of inseminating as many turkey hens as possible and to maintain the fertilizing capacity of the sperm for at least 6 hours, although Abad *et al.* (2003) indicate that in the laboratory they have found a fertilizing capacity of 24 to 48 hours after ejaculation, Another way to maintain an acceptable level of fertility for up to 6 hours is indicated by Barbas and Mascarenhas (2009) who indicate that after the bird has ejaculated it is necessary to reduce the physiological temperature gradually from 41 to 4 °C in order to decrease metabolic activity, which will extend the life of the spermatozoa. The viability of undiluted semen is reduced 20 to 30 minutes after collection, so it should be used quickly (Abad *et al.*, 2003).

Semen extraction and collection. Various methods are used to collect semen from birds (dorsal-abdominal massage, interruption of copulation, washing of vas deferens), although the most commonly used is the dorsal-abdominal massage proposed by Burrows and Quinn (1937). One or two persons can perform semen extraction, depending on the ability of the operators to hold the turkey and massage it at the same time. One way is to remain seated or standing with the bird in one of the arms and with the hand of the same arm where the animal is resting hold the bird's legs, and with the other hand perform a light but firm massage on the back of the turkey, in a cranial-caudal direction (Figure 5A). In each massage, the operator's index finger and thumb reach the cloaca and can be continued to the tip of the tail. When the male is stimulated, the cloaca is everted by pressing it to expose the erectile papilla, awaiting the ejaculate through the seminal groove, to be collected by aspiration (Figure 5B).

Postmortem collection. This technique can be of great help for birds of high genetic value. It consists in collecting the vas deferens of the dead bird by postmortem dissection (Figure 6A) and in each one of them introduce a needle or cannula with saline solution or with some diluent to wash and obtain the semen from each one of them (Figure 6B).

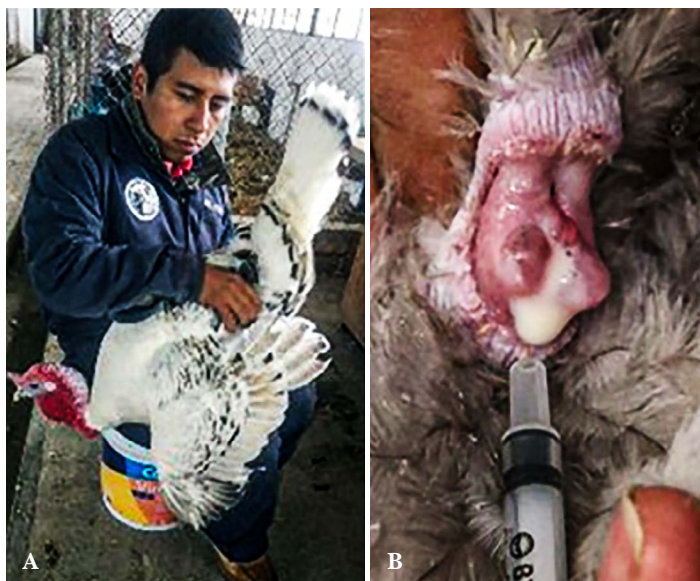

Figure 5. Semen extraction and recollection. A) Dorsal ventral massage. B) Eversion of the erectile papilla and collection of ejaculate.

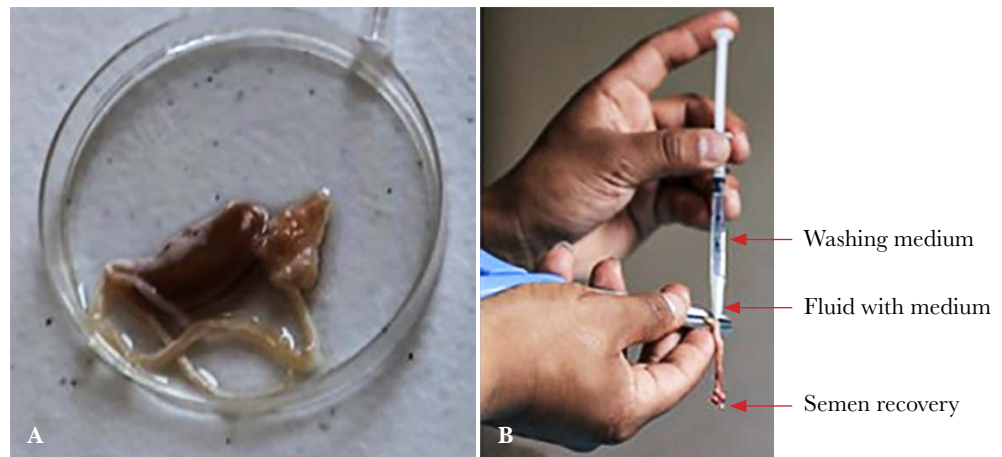


Figure 6. Postmortem semen recovery. A) Dissection of the vas deferens, B) washing of the vas with fluid for seminal collection.

CONCLUSIONS

The anatomical, morphological, physiological, and reproductive characteristics native Mexican turkeys were documented. The knowledge of these characteristics will allow the development of reproductive strategies to improve the productive and reproductive efficiency of the native Mexican turkey.

REFERENCES

- Abad, M., Castelló, L.I.J.C., Carbajo, G.E., Casanovas, I.P., Dalmau, B.A., García, M.E., Leva, G.R., Martínez-Alesón, S.R. (2003). *Reproducción e incubación en avicultura*. Real Escuela de Avicultura, Barcelona, España.
- Bakst, M.R., Akuffo, V. (2008). Turkey Sperm reside in the tubular glands in the urodeum following artificial Insemination. *Poultry Science*, 87, 790-792. Doi: 10.3382/ps.2007-00293
- Barbas, J., Mascarenhas, R. (2009). Cryopreservation of domestic animal sperm cells. *Cell and Tissue Banking*, 10(1), 49-62.
- Bentley, G.E., Jensen, J.P., Kaur, G.J., Wacker, D.W., Tsutsui, K., Wingfield, J.C. (2006). Rapid inhibition of female sexual behavior by gonadotropin-inhibitory hormone (GnIH). *Hormones and Behavior*, 49, (4) 550-555. Doi: 10.1016/j.yhbeh.2005.12.005
- Brandstätter, R. (2003). Encoding time of day and time of year by the avian circadian system. *Journal of Neuroendocrinology*, 15(4), 398-404. Doi: 10.1046/j.1365-2826.2003.01003.x.
- Burrows, W., Quinn, J. (1937). The collection of spermatozoa from the domestic fowl and turkey. *Poultry Science*, 15, 19-24.
- Crawford, R.D. (1992). Introduction to Europe and diffusion of domesticated turkeys from the America. *Archivos de Zootecnia*, 41(extra), 307-314.
- Gee, G.F., Bertschinger, H., Donoghue, A.M., Blanco, J.M., Soley, J. (2004). Reproduction in non-domestic birds: physiology, semen collection, artificial insemination and cryopreservation. *Avian Poultry Biology Reviews*, 15, 47-101.
- González-Santos, J. A.; Ávalos-Rodríguez, A.; Martínez-García, J. A.; Rosales-Torres, Herrera-Barragán, J. A. (2019). Sperm morphophysiology in different sections of the rooster reproductive tract. *International Journal of Morphology*, 37(3): 861-866.
- Hardeland, R., & Fuhrberg, B. (1996). Ubiquitous melatonin-Presence and effects in unicells, plants and animals. *Trends in Comparative Biochemistry & Physiology*, 2, 25-45.
- Herrera, J.A., Ávalos, R.A., González, S.J.A., & Rosales, T.A.M. (2014). Técnicas de reproducción asistida en aves domésticas y silvestres. Manual No 41 CBS. Universidad Autónoma Metropolitana-X. México.
- Illnait-Ferrer, J. (2012). Melatonina: actualidad de una hormona olvidada. *Revista CENIC. Ciencias Biológicas*, 43(3).

- López, P.E., Uriostegui, R.E., López, P.F., Pro, M.A., Hernández, M.O., Guerrero S.J.I. (2011). Calidad nutricional de pechuga, muslo y pierna de guajolotas y guajolotes nativos mexicanos (*Meleagris gallopavo* L.). *Actas Iberoamericanas de Conservación Animal*, 1, 338-341.
- Ramírez, C.O.Y., Ramírez, S.E. (2012). Relaciones filogenéticas y morfológicas de poblaciones nativas de guajolotes (*Meleagris gallopavo* Linn) utilizando marcadores moleculares AFLP`S. [Tesis Profesional. Departamento de Zootecnia. Universidad Autónoma Chapingo]. 51 p.
- Ricaurte, G.S.L. (2006). Importancia de un buen manejo de la reproducción en avicultura. *Revista Electrónica de Veterinaria* 7(4), 1-16.
- Tsutsui, K., Ubuka, T., Yin, H., Osugi, T., Ukena, K., Bentley, G.E., Ciccone, N., Inoue, K., Chowdhury, V.S., Sharp, P.J. (2006). Mode of action and functional significance of avian gonadotropin inhibitory hormone (GnIH): a review. *Journal of Experimental Zoology Part A: Comparative Experimental Biology*, 305(9), 801-806.

